

# A Rare Mucoepidermoid Carcinoma of the Lacrimal Gland

**Wendy Zhen,**  
**OD, FAAO, DiplABO**  
University of California,  
San Francisco

**Alanna Khattar-Sullivan,**  
**OD, FAAO, DiplABO**  
BronxCare Health System

---

## ABSTRACT

---

This case report demonstrates the importance of ruling out orbital masses as an etiology in cases of non-resolving proptosis, upper eyelid edema, and diplopia. This report also reviews the key testing required to properly identify or rule out orbital masses.

A 40-year-old African American male presented for persistent right upper eyelid edema, proptosis, and diplopia in up-gaze following a physical assault more than one year previously. Extraocular muscle testing revealed moderate restriction in up-gaze and mild restriction in abduction of the right eye. Anterior segment examination was remarkable for moderate right upper eyelid chemosis and proptosis. Magnetic resonance imaging (MRI) of the orbits revealed a mass originating from the right lacrimal gland with marked proptosis of the right globe. Biopsy results of the right lacrimal gland mass supported a diagnosis of rare intermediate- to high-grade mucoepidermoid carcinoma of the right lacrimal gland. Management included surgical removal of the lacrimal gland tumor, treatment of keratoconjunctivitis sicca following excision of lacrimal gland tissue, and long-term co-management by oculoplastics and oncology.

Proptosis, upper eyelid edema, and/or diplopia can be expected after a recent ocular trauma, but more serious etiologies can have similar presentations. This case report highlights the importance of further investigation and neuro-imaging when a patient presents with these types of non-resolving clinical signs.

## KEY WORDS:

Mucoepidermoid carcinoma, lacrimal gland tumor, proptosis, chemosis, diplopia, extraocular muscle restriction

## INTRODUCTION

In many cases of ocular trauma, common presenting signs and symptoms include proptosis and eyelid edema. In some cases, the patient may also have diplopia due to muscle entrapment from an orbital wall fracture. Although these may be typical signs in an acute ocular trauma, an orbital mass can present with similar signs and may be masked if the timing of trauma overlaps the initial presentation of the orbital mass.

Orbital tumors can be benign or malignant and can originate from the orbit or nearby sources, or metastasize from another part of the body. As the mass grows, the most common ocular signs include proptosis and displacement of the globe away from the location of the tumor. Depending on the size, origin, and type of tumor, patients can be symptomatic for diplopia, pain, and possible vision loss. If an orbital mass is discovered, it is imperative to perform a biopsy to determine if the tumor is malignant and if there is a risk of primary or secondary metastasis. In this report, a case of mucoepidermoid carcinoma (MEC) was diagnosed, treated, and managed. MEC is a common malignant epithelial tumor of the salivary glands, but is exceedingly rare in the lacrimal gland. MEC of the lacrimal gland usually presents as an isolated, painless, and slow-growing mass.

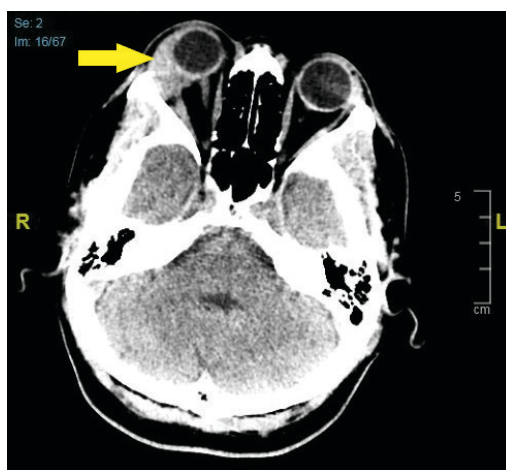Tumors are categorized into three grades based on the proportion of cellular types (mucous, epidermoid, and intermediate cells), cytological features, and nuclear atypia seen histologically. Prognosis is solely dependent on the histological grade of the tumor.

**CASE REPORT**

A 40-year-old African American male presented complaining of persistent right upper eyelid edema, proptosis, and diplopia in up-gaze since right orbital trauma from a physical assault more than one year previously. The patient reported being evaluated at an outside hospital at the time of his physical assault. He did not have records or reports of that visit, but recalls that the imaging performed at the time was unremarkable. His condition had not been further evaluated since the initial encounter one year previously. He did not recall his last eye exam and did not wear any optical correction. He reported a past ocular history of two different occurrences of Bell’s palsy (left-sided five years prior and right-sided three years prior), resulting in incomplete eyelid closure of the right eye. His medical history consisted of hyperlipidemia, bipolar disorder, human immunodeficiency virus, gastroesophageal disease, fatty liver, and herpes zoster. Medication use included amitriptyline, esomeprazole, furosemide, a combination of elvitegravir/cobicistat/emtricitabine/tenofovir alafenamide (Genvoya), paroxetine, and pravastatin.

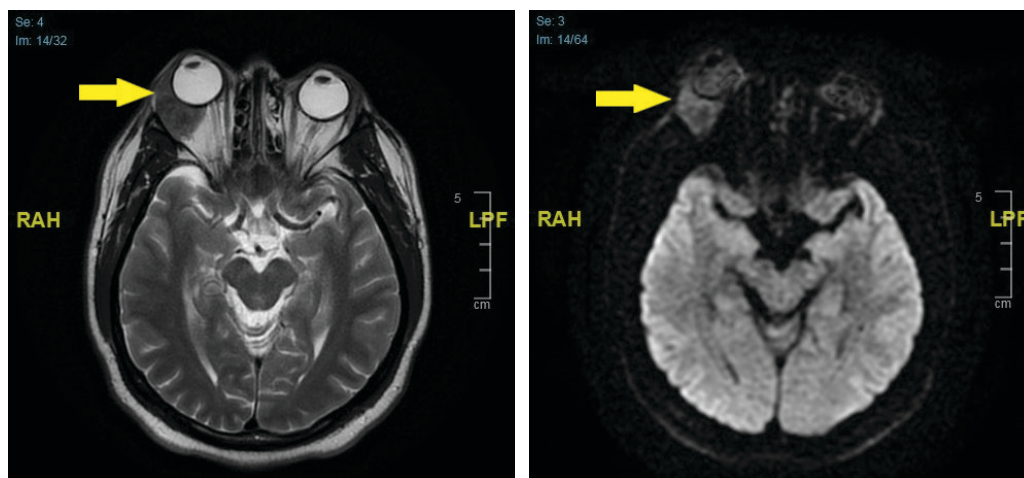
Ocular examination revealed uncorrected distance acuities of 20/20 (6/6) OD and OS. Careful extraocular motility assessment revealed both moderate restriction in up-gaze and mild restriction in abduction OD. The patient reported diplopia in up-gaze, especially when looking up to the right. No tropia or phoria in primary gaze was noted by a cover test at distance or near. Pupils and confrontation visual fields were normal in both eyes. Anterior segment examination was remarkable for moderate upper eyelid chemosis, incomplete eyelid closure, and proptosis OD. Proptosis of the right eye was confirmed with Hertel exophthalmometry measurements. With a base of 104 mm, measurements were 25mm OD and 22mm OS. Intraocular pressures were 13 mmHg OD and 13 mmHg OS by Goldmann tonometry. Dilated fundus examination was remarkable for a partial posterior vitreous detachment and white without pressure superior temporal in the periphery OD and unremarkable OS. At this point, the patient was sent for a computed tomography (CT) scan without intravenous contrast of the head and orbits and referred to the oculoplastics specialist for evaluation.

**Figure 1:** CT scan of head without contrast revealed a mass located superior temporal to the right eye.

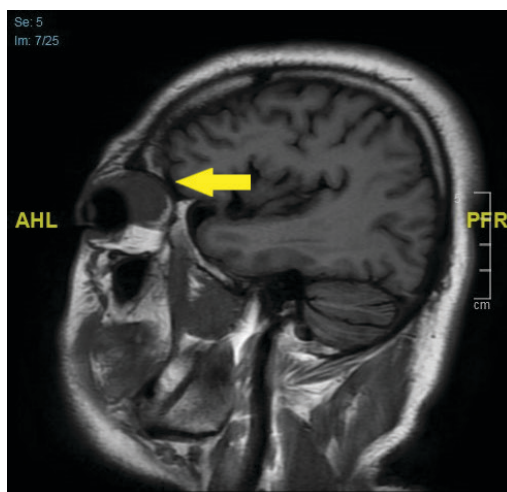


CT scan of the head revealed the presence of a mass superior temporally in the right orbit (Figure 1). Magnetic resonance imaging (MRI) with and without intravenous contrast of the head and orbits was then ordered to obtain better imaging detail of the soft tissue mass. The MRI report noted an enhancing mass within the superior lateral margin of the right orbit measuring 2.3 x 2.0 x 2.0 cm, likely originating from the right lacrimal gland, with marked proptosis of the right globe (Figures 2A, 2B, and 3).

**Figure 2A and B:** MRI of head and orbits without contrast. Axial T2-weighted (2A) and axial diffusion weighted image (2B) showed an enhancing mass within the superior lateral margin of the right orbit measuring 2.3 x 2.0 x 2.0cm, originating from the right lacrimal gland.



**Figure 3:** MRI of head and orbits without contrast. Sagittal T1-weighted image displaying an orbital mass of the right lacrimal gland.



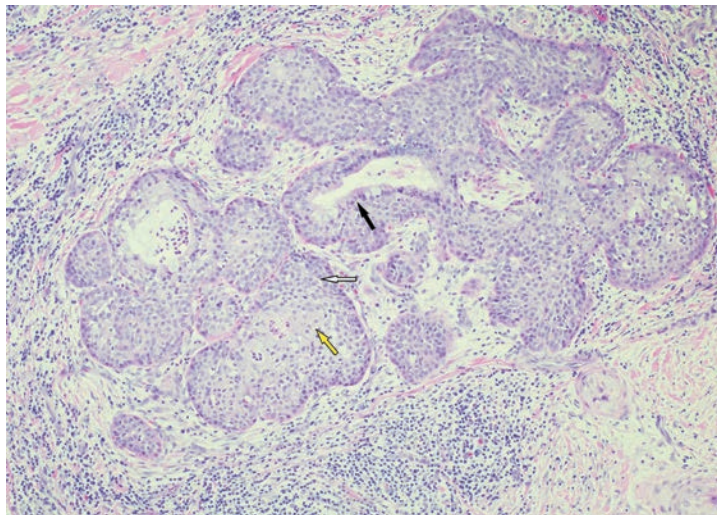
Differential diagnoses of the mass seen on the MRI included pleomorphic adenoma, a fibrous tumor of the orbit, orbital inflammatory pseudotumor (ocular adnexal sarcoidosis), orbital lymphoma, and MEC. Based on the findings of MRI of the orbits, a biopsy of the orbital mass was ordered and performed promptly.

Biopsy results of the right lacrimal gland mass led to the diagnosis of a rare intermediate- to high-grade MEC of the right lacrimal gland (Figure 4). The biopsy was essential in making the diagnosis of MEC of the lacrimal gland. Management included complete lacrimal gland tumor excision by an oculoplastic surgeon. A post-operative MRI of the head and orbits with and without intravenous contrast was recommended.

The patient had expressed anxiety and refused MRI after lacrimal gland tumor removal due to claustrophobia; therefore, a post-operative CT scan of the orbits with and without intravenous contrast was obtained. The CT re-

port confirmed complete removal of the right lacrimal gland and tumor without evidence of residual tumor. The patient was then referred to oncology for continued management and consideration for adjuvant radiation treatment.

**Figure 4:** *Histological slide of the right lacrimal gland tumor biopsy stained with hematoxylin and eosin. Based on the proportion of epidermoid (squamous) cells (yellow arrow), intermediate cells (white arrow), and mucous cells (black arrow) seen histologically, a diagnosis of an intermediate- to high-grade MEC of the right lacrimal gland was made.*



At the 1-month post-operative visit, the patient presented with a complaint of severe right eye pain. He reported improvement of the right upper eyelid edema and diplopia. Extraocular motility assessment revealed only mild restriction in up-gaze, much improved compared to before surgery, and stable mild abduction deficit of the right eye. There was noticeable improvement in proptosis subjectively and objectively on the post-operative CT scan images and Hertel exophthalmometry set at base 104 mm; 23 mm OD and 22 mm OS. Pre-operative measurements showed a 3 mm difference between the two eyes, compared to the 1 mm difference post-operatively. Anterior segment evaluation revealed 3+ diffuse superficial punctate keratitis (SPK) OD, trace SPK OS, and instantaneous tear break up time (TBUT) OD. Management consisted of preservative-free artificial tears every 1-2 hours and artificial tear ointment at bedtime OD. The patient will also be followed long-term with the oculoplastics specialist and will be co-managed with oncology and adjuvant radiotherapy as needed.

**DISCUSSION**

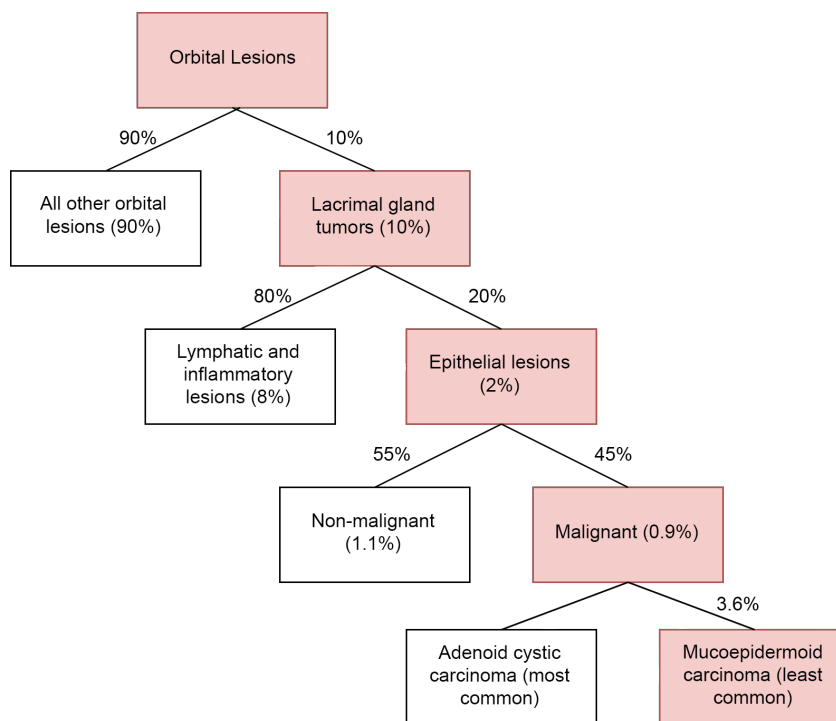
In this case, the patient’s concurrent trauma may have confounded his initial diagnosis. In a patient with non-resolving proptosis and upper eyelid edema, it is crucial to consider a possible orbital mass. Neuro-imaging is necessary to identify the presence and location of an orbital mass. Once a mass was identified, a biopsy was essential in making the diagnosis of MEC of the lacrimal gland.

The incidence of orbital tumors is 1.59 per million person-years and lacrimal gland tumors are much more rare, at an incidence of 0.43 per million person-years.<sup>1</sup> Of the 10% of orbital lesions that are lacrimal gland tumors, epithelial lesions comprise about 20%.<sup>2,3</sup> Forty-five percent of epithelial lesions are malignant, with the least common of these being MEC, which comprise only 3.6% (Figure 5).<sup>2,3</sup>

MEC is more frequently found in the salivary glands and is extremely rare in the lacrimal gland. MEC is diagnosed slightly more often in females (3:2) and often presents at a mean age of approximately 50 years.<sup>4</sup> Pathological diagnosis and prognosis of MEC are based on the proportions of epidermoid (squamous) cells, intermediate cells, and mucous cells seen histologically. Low-grade MEC appears well-differentiated and consists of over 50% mucous cells. In contrast, high-grade MEC is poorly differentiated and primarily composed

of squamous and intermediate cells, with less than 10% mucous cells. Intermediate-grade exhibits histologic features of both low- and high-grade MEC.<sup>5</sup> Management for low-grade tumors involves referral to an oculo-plastic specialist for extirpation and radiation oncology for possible adjuvant radiation. High-grade tumors are treated with exenteration, radiation, and resection of the involved orbital bone.<sup>5</sup> The need for chemotherapy is generally reserved for recurrent and metastatic cases.<sup>6</sup>

**Figure 5:** Incidence of orbital tumors, demonstrating that mucoepidermoid carcinoma is the least common malignant orbital tumor.<sup>2,3</sup>



In a study of 50 patients with MEC of the head and neck who were followed until disease recurrence or death, 100% of patients with low-grade remained alive and cancer-free, 77% of patients with intermediate-grade remained cancer-free while 0% died of disease, and 52% of high-grade patients died of disease.<sup>7</sup> High-grade MEC of the lacrimal gland can metastasize to the lung, brain, or mediastinum.<sup>5</sup> There are only two reported cases of patients with high-grade MEC treated with orbital exenteration and adjuvant radiation who have survived.<sup>5</sup>

When treatment of the tumor involves surgical removal of the lacrimal gland, dry eye signs and symptoms are expected post-operatively. There is a decrease in reflex secretion and an increase in symptomatic dry eye initially following lacrimal gland removal. Ocular surface signs and patient symptoms are expected to improve within six months as the accessory lacrimal glands compensate by increasing secretion.<sup>8,9</sup> Patients should be treated long-term as aqueous-deficient dry eye.

Although rare, patients with high-grade MEC have a worse prognosis due to a higher rate of recurrence and possibility of distant metastases compared to intermediate-grade and low-grade tumors (Table 1).<sup>7</sup> Given the overall poor prognosis, this patient with intermediate- to high-grade MEC was treated with prompt surgical intervention and adjuvant radiotherapy. He will continue to be followed closely and co-managed by oncology and oculoplastics for recurrence and metastasis.



**Table 1:** Percentage of recurrence and distant metastases based on the histological grading of head and neck mucoepidermoid carcinoma.<sup>7</sup>

Grade	Recurrence	Distant Metastases
Low	0%	0%
Intermediate	23%	0%
High	30%	13%

**CONCLUSION**

In cases of non-resolving proptosis, eyelid swelling, and diplopia, it is essential to rule out the presence of an orbital mass. Imaging is essential in determining if a mass is present in cases of proptosis. In this case, further investigation with neuro-imaging led to the diagnosis of MEC, which was potentially life-saving. Biopsy is pivotal to the diagnosis, treatment, and prognosis in these cases. It is important to educate the patient on the expected development of dry eye symptoms following lacrimal gland excision. The patient can be reassured that there is an expected improvement and possible resolution of dry eye symptoms over time. Co-management of patients with intermediate- to high-grade MEC with oncology is critical due to the risk of recurrence and metastasis. With frequent follow-up and regular repeated imaging, any recurrence may be caught early and treatment can be initiated immediately. ●

**CORRESPONDING AUTHOR**

Wendy Zhen, OD – wzhenod@gmail.com

**REFERENCES**

- Hassan WM, Bakry MS, Hassan HM, et al. Incidence of orbital, conjunctival, and lacrimal gland malignant tumors in USA from Surveillance, Epidemiology and End Results 1973-2009. *Int J Ophthalmol* 2016;9(12):1808-13.
- Daniel L. Mucoepidermoid carcinoma ex pleomorphic adenoma of the lacrimal gland: A rare presentation. *Indian J Ophthalmol* 2014;62(6):743-6.
- Totuk Gedar OM, Demir MK, Yapicier O, et al. Low-grade mucoepidermoid carcinoma of the lacrimal gland in a teenaged patient. *Case Rep Ophthalmol Med* 2017;2017:1-4.
- Von Holstein SL. Tumours of the lacrimal gland. Epidemiological, clinical and genetic characteristics. *Acta Ophthalmol* 2013;91(6):1-28.
- Hwang SJ, Kim KH. High-grade mucoepidermoid carcinoma of the lacrimal gland. *Korean J Ophthalmol* 2018;32(5):426-7.
- Guimaraes DM, Almeida LO, Martins MD, et al. Sensitizing mucoepidermoid carcinomas to chemotherapy by target disruption of cancer stem cells. *Oncotarget* 2016;7(27):42447-60.
- Nance MA, Seethala RR, Wang Y, et al. Treatment and survival outcomes based on histologic grading in patients with head and neck mucoepidermoid carcinoma. *Cancer* 2008;113(8):2082-9.
- Zhang YQ, Qian J, Yuan YF, Xue K, Guo J, Wang XN. [Tear film and lacrimal excretion changes after lacrimal gland tumor removal]. *Zhonghua Yan Ke Za Zhi* 2013 Jan;49(1):27-31. (in Chinese)
- Maitchouk DY, Beuerman RW, Ohta T, et al. Tear production after unilateral removal of the main lacrimal gland in squirrel monkeys. *Arch Ophthalmol* 2000;118(2):246-52.