

An Uncommon Presentation of Pigmented Paravenous Retinochoroidal Atrophy

Raman Bhakhri, OD, FAAO
Illinois College of Optometry,
Chicago, IL, USA

Kevin Patel, MD
Retina Associates

Abstract

Pigmented paravenous retinochoroidal atrophy (PPRCA) is a rare diagnosis of exclusion as it can mimic many hereditary retinal (namely retinitis pigmentosa), infectious, and inflammatory disorders. Once diagnosed, it carries a favorable prognosis due to the macula being spared with slow to no progression and a lack of symptoms. However, rare cases have shown macular involvement and symptoms including nyctalopia. Clinicians should be aware of presentations of PPRCA, beyond the typical findings noted in the literature, as these cases could be misdiagnosed. This case report details a rare presentation of PPRCA with macular involvement and nyctalopia. A review of common and uncommon findings, potential pathophysiology, differential diagnoses, and multimodal imaging results is also presented.

KEY WORDS: pigmented paravenous retinochoroidal atrophy, retinitis pigmentosa, multimodal imaging

INTRODUCTION

Pigmented paravenous retinochoroidal atrophy (PPRCA) is a rare disorder of the retina and choroid. Although the etiology is unknown at this time, inflammatory and hereditary pathologies have been postulated.¹⁻³ The condition is characterized by retinal pigment epithelium atrophy and photoreceptor degeneration, choriocapillaris atrophy, and namely, pigment accumulation around retinal veins radiating from the optic nerve. The condition tends to present bilaterally and symmetrically with little to no progression noted in case reports and series.^{4,5} As the condition tends to spare the macula, most patients are asymptomatic and the diagnosis is made by chance upon retinal examination. This case report details an uncommon presentation of PPRCA in which the diagnosis was made based on ocular history, multimodal imaging, and the results of laboratory and genetic testing.

CASE REPORT

A 25-year-old black male presented for a comprehensive eye exam with a chief complaint of reduced vision for distance and near in both eyes along with not being able to find his seat in a dimly lit movie theater. These symptoms were consistent with nyctalopia. The patient reported that his decreased vision had started 10 years prior and that he had been diagnosed by previous providers with retinitis pigmentosa; genetic testing had not been performed when the previous records were reviewed. Both his ocular and medical history and his family's ocular and medical history were otherwise unremarkable. The best corrected visual acuity was 20/300 in the right eye and 20/70 in the left eye. External examination, entrance testing, and slit lamp examination findings were unremarkable. Intraocular pressures were 12 mmHg in both eyes by Goldmann applanation tonometry. Fundus examination revealed optic discs with a 0.25/0.25 cup-to-disc ratio in both eyes with no evidence of pallor. Macular mottling with retinal sheen was noted in both eyes. Retinal pigment accumulation was present adjacent to and around retinal veins that radiated from the optic nerve in both eyes (Figure 1). No vessel attenuation was present. Fundus autofluorescence revealed

hypoautofluorescence with surrounding hyperautofluorescence also radiating from the optic nerve and following the course of the retinal veins into the mid periphery (Figure 2). The extensive hypoautofluorescence in the midperiphery, indicative of retinal pigment epithelium atrophy, likely accounted for the patient’s complaints of nyctalopia. Spectral domain optical coherence tomography of the macula revealed perifoveal loss of the ellipsoid zone and interdigitation zone and thinning of the retinal pigment epithelium which likely accounted for the patient’s reduced acuities. Spectral domain optical coherence tomography was also performed in and around the retinal veins and revealed retinal pigment accumulation in the inner and outer retina accompanied by posterior shadowing along with choriocapillaris atrophy (Figure 3).

Due to the patient’s entering history and clinical examination, PPRCA was suspected. An inherited retinal disease panel was scheduled to rule out the initial diagnosis of retinitis pigmentosa or any other inherited retinal disease. Uveitic laboratory testing was also ordered to rule out any infectious or inflammatory etiology. Testing included syphilis IgG, QuantiFERON Gold, angiotensin-converting enzyme, serum lysozyme, complete blood count, and herpes simplex titers, and cytomegalovirus titers. The patient returned one month later for a follow-up visit and to review his test results. The ocular examination findings were unchanged from those in his previous exam. The inherited retinal disease panel was negative for any inherited retinal disease while the lab testing for infectious and inflammatory diseases was also unremarkable. Visual field testing and electrodiagnostic testing were considered, however the findings vary between known PPRCA cases (see Discussion). Also, many conditions (see differentials) can exhibit similar findings. Therefore, these tests were not performed. Based on the examination findings and normal laboratory and genetic testing, the patient was diagnosed with PPRCA. Subsequent examination by a retinal specialist confirmed the diagnosis. The patient was referred for low-vision rehabilitation and continues to be followed, with the last visit showing stable findings.

Figure 1: Ultra-wide field fundus photographs of the left eye and right eye revealing retinal pigment accumulation adjacent to and around retinal veins radiating from the optic nerves and extending into the midperiphery.

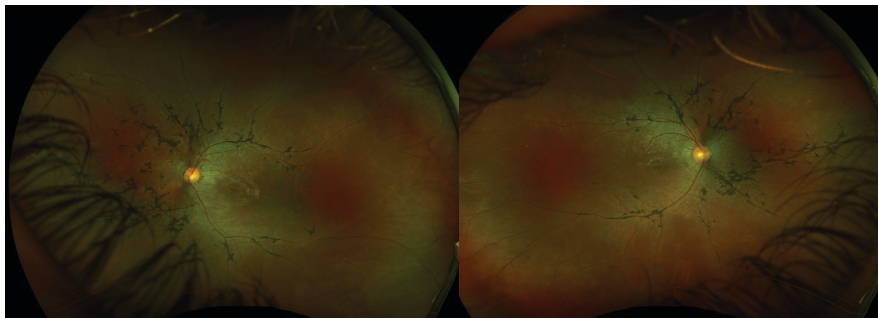


Figure 2: Fundus autofluorescence of the left eye and right eye showing hypoautofluorescence with surrounding hyperautofluorescence also radiating from the optic nerve and following the course of the retinal veins into the midperiphery. The extensive hypoautofluorescence in the midperiphery is indicative of retinal pigment epithelium damage and atrophy.

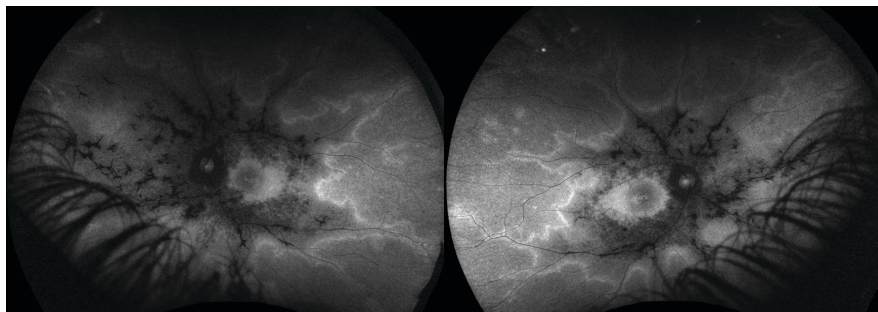
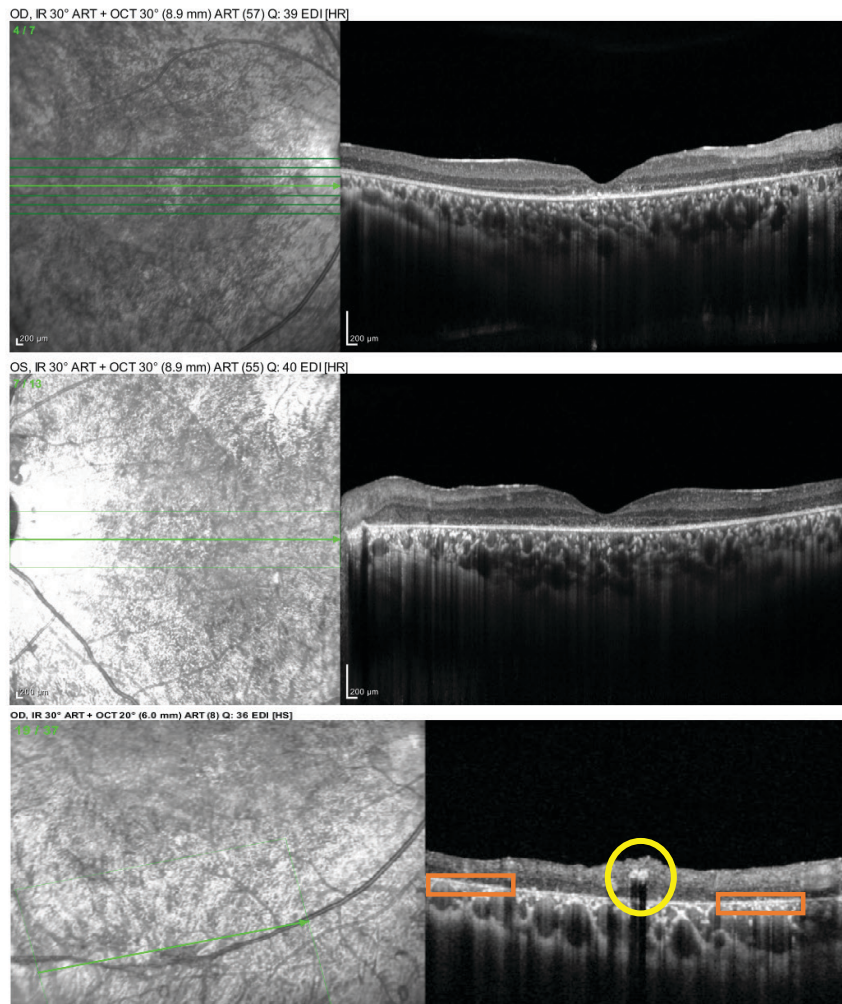


Figure 3: Spectral domain optical coherence tomography of the macula revealed perifoveal loss of the ellipsoid zone and interdigitation zone, and thinning of the retinal pigment epithelium in the right (top image) and left eye (middle image) which likely accounted for the patient's reduced acuities. Spectral domain optical coherence tomography was also performed in and around the retinal veins (bottom image), and revealed retinal pigment accumulation accompanied by posterior shadowing (yellow circle). Choriocapillaris atrophy is also present around areas of paravenous involvement (orange rectangles).



DISCUSSION

PPRCA is a rare disease of the retina and choroid. Typically, the condition presents bilaterally and symmetrically as retinochoroidal atrophy with adjacent pigment that follows the course of retinal veins that radiate in a peripapillary manner.¹⁻³ The macula is typically spared and hence most patients are asymptomatic. However, uncommon symptoms have been reported, including vision loss (due to macular involvement), field loss, and nyctalopia. These uncommon symptoms were noted in this patient. Since this condition is rare, the average age of diagnosis has varied between studies. One study noted an average age at diagnosis of 51, while another study noted an average age at diagnosis of 36.^{3,6} Patients also vary widely in age; anywhere from 29 to 82 years of age, with no gender tendency.³

The etiology of PPRCA is still unknown. Various theories have been postulated, including that it may be an inherited disorder. McKay et al. noted a PPRCA phenotype, with variable expressivity in a family mutation in the *CRB1* gene.⁷ However, further studies and review have failed to find a genetic linkage. Other causes have been thought to include inflammatory and infectious precursors. It is well established that cases with a

In your patients with moderate-to-severe keratoconjunctivitis sicca (dry eye),

Discover increased tear production with CEQUA™

PrCEQUA™ (cyclosporine ophthalmic solution, 0.09% w/v) is indicated to increase tear production in patients with moderate-to-severe keratoconjunctivitis sicca (dry eye).



CEQUA is formulated with nanomicelle technology*

*Clinical significance is unknown

 **Cequa**[™]
(cyclosporine ophthalmic solution) 0.09%


SUN
PHARMA

Clinical use:

Pediatrics (<18 years of age): The safety and efficacy of CEQUA has not been established in pediatric patients; therefore, Health Canada has not authorized an indication for pediatric use.

Geriatrics (>65 years of age): No overall differences in safety or effectiveness have been observed between elderly and younger adult patients.

Contraindications:

- Patients who are hypersensitive to this drug or to any ingredient in the formulation or component of the container
- Patients with active or suspected ocular or peri-ocular infections
- Patients with ocular or peri-ocular malignancies or premalignant conditions

Relevant warnings and precautions:

- For topical ophthalmic use only
- Resolve existing or suspected ocular or peri-ocular infections before initiating CEQUA treatment. If an infection occurs during treatment, CEQUA should be temporarily withheld until the infection has been resolved
- Patients should be advised not to drive or use machines until their vision has cleared after CEQUA administration
- CEQUA has not been studied in patients with a history of *herpes keratitis*, end stage lacrimal gland disease, keratoconjunctivitis sicca (KCS) secondary to the destruction of conjunctival goblet cells such as occurs with Vitamin A deficiency, or scarring, such as occurs with cicatricial pemphigoid, alkali burns, Stevens-Johnson syndrome, trachoma, or irradiation
- Patients with severe keratitis should be carefully monitored
- Potential for eye injury and contamination
- CEQUA should not be administered while wearing contact lenses
- Local infections and malignancies: Regular monitoring of the eye(s) is recommended when CEQUA is used long term
- Hypersensitivity reactions
- The effect of CEQUA has not been studied in patients with renal or hepatic impairment
- CEQUA is not recommended during pregnancy unless the benefits outweigh the risks
- Caution should be exercised when CEQUA is administered in nursing women

For more information:

Please consult the Product Monograph at https://pdf.hres.ca/dpd_pm/00060038.PDF for important information relating to adverse reactions, interactions and dosing information, which has not been discussed in this piece. The Product Monograph is also available by calling our medical department at 1-844-924-0656.

REFERENCE: Current CEQUA™ Product Monograph, Sun Pharma Global FZE.

© 2022 Sun Pharma Canada Inc. All rights reserved.

CEQUA is a trademark of Sun Pharma Global FZE. Used under license.



PPRCA-like presentation can occur following diseases such as measles, syphilis, Behcet's disease, and various other uveitic conditions.^{1,3} As this fundus appearance has a true underlying etiology, many have termed it pseudo PPRCA, with true PPRCA being reserved as a diagnosis of exclusion.¹ Our patient's uveitis testing was noted to be normal, and hence it was unlikely that the patient had pseudo PPRCA. Other appropriate differentials should also be considered, with the main differential being retinitis pigmentosa.

- **Retinitis pigmentosa:** as it is an inherited retinal disorder, family history can be useful in addition to genetic testing that can be performed to screen for any potential mutations. Other signs that are seen more often in retinitis pigmentosa than PPRCA include optic nerve pallor, significant complaints of nyctalopia, and vessel attenuation.³ Bone spicules, or pigment accumulation, are seen around arteries and veins compared to predominant venous involvement with PPRCA, as seen in this patient. The condition is also quite progressive compared to PPRCA. Although the patient in this case report had complaints of nyctalopia, genetic testing and fundus appearance (lack of bone spicules, lack of nerve pallor, and lack of retinal arterial involvement) excluded retinitis pigmentosa.
- **Syphilis:** a bacterial infection secondary to *Treponema pallidum*. It is known to vary in its presentation but can result in pigmentary retinopathy similar to PPRCA.¹ Active or previous infections of syphilis can be verified through standard blood testing.⁸ Standard syphilis testing for this patient was negative.
- **Serpiginous chorioretinopathy:** A progressive condition classified under the white dot syndromes that presents with large amounts of chorioretinal atrophy that radiate from the optic nerve in a snake-like fashion. At times, it has been associated with tuberculosis.^{1,9} However, lab testing for tuberculosis was negative and the retinal appearance did not support serpiginous chorioretinopathy.
- **Angioid Streaks:** these linear streaks radiate from the optic nerve, in a similar fashion to PPRCA, and represent breaks in Bruch's membrane. The term angioid means resembling a blood vessel, hence they can be confused with normal blood vessels leaving the optic disc. They can also be associated with systemic conditions such Pseudoxanthoma elasticum, Ehler-Danlos syndrome, Paget's disease, and Sickle cell disease.¹⁰ At times, the streaks are idiopathic with no known cause. Our patient's history was not significant for any of these systemic conditions. The patient's fundus appearance also did not correspond to that of a patient with angioid streaks.

- Helicoid peripapillary chorioretinal degeneration: a rare hereditary condition that presents with atrophic chorioretinal degeneration that radiates from the optic nerve outwards to the retinal periphery. The condition is secondary to TEAD1 mutations and is largely seen in patients of Icelandic origin.¹¹ Genetic testing was negative for TEAD1 mutation in our patient.

With the etiology of PPRCA still to be determined, an underlying pathophysiology is also difficult to ascertain. However, it has been long established that the retina and choroid are the two main sites of involvement. Barteselli commented on how choroidal thinning precedes damage to the choroid. It was once thought that reduced blood flow secondary to this thinning led to outer retinal dysfunction (photoreceptor atrophy followed by retinal pigment epithelium atrophy).¹² The study by Lee et al. also strengthened this hypothesis, as they observed visible choroidal thinning with an undisturbed retinal pigment epithelium in some patients.³ This evidence seems to support the theory of choroidal thinning leading to outer retinal damage. However, further investigations will be needed to identify the exact mechanism involved in the development of PPRCA.

Although the diagnosis can be made based on fundus observation and the results of testing outside the clinical setting, multimodal imaging can aid in arriving at a final diagnosis more promptly and with more confidence. However, clinicians should note that none of the test results are pathognomonic for PPRCA, since similar results can also be seen with the previously listed differential diagnoses.

Fundus autofluorescence is considered to be the best imaging modality as it excels at capturing the extent of retinochoroidal atrophy associated with PPRCA lesions. This is seen as separation lines between the currently affected (hyperautofluorescence) and previously affected/damaged (hypoautofluorescence) areas.^{2,3,13} Specific areas of hypoautofluorescence should correspond to areas of outer retinal damage as evidenced by fluorescein angiography and optical coherence tomography.² Various fundus autofluorescence patterns can be present in patients so multiple classifications have been suggested.^{3,6} The most recent of these systems classifies the extent of the retinochoroidal lesions into three categories, paravenous, focal, and confluent, with paravenous being the most common type.³ Paravenous fundus autofluorescence patterns show a continuous hypoautofluorescence pattern that is surrounded by hyperautofluorescence along the course of retinal veins. This is likely the pattern seen in our patient. The focal subtype lacks this continuous appearance and shows separation of lesion autofluorescence. Lastly, the confluent subtype is characterized by large areas of hypoautofluorescence that extend outside the posterior pole.³ Based on this classification system, our patient was diagnosed with the paravenous subtype of PPRCA.

Optical coherence tomography will reveal marked damage to the outer retina which can involve all or part of the ellipsoid zone, the interdigitation zones, as well as the retinal pigment epithelium.¹³ For the most part, the inner retina is spared, which coincides with sparing of the retinal vessels and hence a normal retinal vasculature appearance compared to retinitis pigmentosa.² Similar findings were noted with our patient. Other rare findings that have been reported include macular pucker, cystoid macular edema, and lamellar and full-thickness macular holes.^{6,14} Specific scanning through the paravenous areas is notable for thinning of the outer retina and retinal pigment epithelium migration encompassing some or all of the retinal layers with a corresponding shadowing effect.^{2,3,5} This was seen in our patient. Adding to Barteselli's theory of primary choroidal involvement, it has been observed that the choroidal thickness is reduced before retinal pigment epithelium atrophy manifests near areas of paravenous involvement.^{3,12} Further evidence of initial choroidal involvement is also seen with optical coherence tomography angiography as areas of poor choroidal circulation in the choriocapillaris or flow voids beneath areas of intact retinal pigment epithelium. These areas of poor perfusion correspond to the findings seen with indocyanine green angiography.^{2,5} In addition, in areas of retinal pigment epithelium atrophy, the retinal capillary plexuses were spared.^{13,15} Although optical coherence tomography angiography was not performed in our patient, choriocapillaris thinning and atrophy was present. This was seen with optical coherence tomography, near areas of paravenous involvement, implying that choroidal circulation is possibly affected (Figure 3). However, not every patient will manifest this presentation. Jung et al. found normal choroidal capillary networks in their case report on a patient with PPRCA.² As optical coherence tomography angiography findings are still being established in the context of PPRCA, further research is required to corroborate these findings and theories.

Fluorescein angiography results will vary depending on the extent of retinochoroidal atrophy. Window defects exhibiting hyperfluorescence will correspond to the atrophy. Retinal pigment epithelium clumping will exhibit

hypofluorescence due to blockage of the underlying fluorescein signal.¹³ Imaging of the choroidal vasculature with indocyanine green angiography will exhibit hypocyanescence in every phase that correlates to retinal pigment epithelium and choroidal atrophy.⁵

Electrodiagnostic testing with electroretinograms is not required for diagnosis as other tests can be more valuable due to the potential for nonspecific and variable findings.¹ Therefore, this testing was not performed on this patient. However, reports have shown normal to minimal responses, and reductions in b-wave amplitude are most commonly observed.^{2,3} Lastly, clinicians can consider performing visual field testing to gauge the amount of potential field loss. Again, findings have been variable, depending on the fundus presentation/degree of retinal pigment epithelium atrophy. Patterns that have been noted in previously published reports include a normal field, ring scotoma, paracentral scotoma, generalized constriction, and enlarged blind spots.^{6,16-18} As the condition presents similar to retinitis pigmentosa with peripheral retinal involvement, kinetic visual field testing is recommended over static visual field testing for cases of PPRCA.¹⁹

As suggested earlier, although most cases tend to be asymptomatic, bilateral, and symmetric, a recent large retrospective study of PPRCA patients revealed that the signs and symptoms are underreported.³ Lee et al. noted that macular involvement was observed in 26% of pigmented PPRCA patients, and almost all of these patients suffered from a significant reduction in vision. This is in stark contrast to other reports which mentioned limited to no macular involvement and loss of acuity.^{1,6} Unfortunately, it is currently unknown why this phenotypic variation occurs in some patients but not in others. This rare phenotypic variation was noted in our patient and accounted for his symptoms, including reduced visual acuity. Next, they found that the prevalence of nyctalopia was 36%, which is much higher than what has been previously reported.^{1,3,6} Nyctalopia was noted subjectively by our patient and electrophysiology was not performed in this case. However, his fundus exam and fundus autofluorescence findings show retinal atrophy extending into the mid periphery corresponding to rod involvement and subsequent nyctalopia. Historically, this condition has been thought to be stable with limited or no structural or functional progression.^{2,6} Although Lee et al. also noted stability in fundus appearance and visual acuity, they obtained two novel findings: structural changes by optical coherence tomography (24% of eyes) and functional progression as evidenced by visual field testing (44.4% of eyes).³ Our patient had subjective disease stability. However, further testing with multimodal imaging will be vital to accurately diagnosis disease progression. While this large case series adds to the body of literature regarding PPRCA, additional studies will still be required to validate these and previous findings. Unfortunately, future studies will possibly be limited due to the scarcity of this condition.

With the exact cause of PPRCA still to be determined, no treatment options exist to prevent outer retinal atrophy. Patients should be followed semi-annually/annually to monitor for any possible disease progression. Patients who present with nyctalopia and a loss of visual acuity should be referred for appropriate low-vision services including orientation and mobility training.

CONCLUSION

This case was diagnosed based on the presenting funduscopic appearance, multimodal imaging, and unremarkable genetic and laboratory testing. Since this condition is often a diagnosis of exclusion, appropriate differentials, as discussed earlier, must be considered and excluded. Clinicians should also be mindful that although patients may present with a diagnosed condition, this does not mean that the diagnosis is correct. In these cases, patients should be re-evaluated, especially when findings do not correlate with presentation or patient history. Although the patient did not fit the typical description of a patient with PPRCA, clinicians should be aware that macular involvement and nyctalopia can occur, despite limited cases reported in the literature. Although no treatment options exist at this time, long-term management and care of patients should include multimodal imaging to detect any possible structural and functional changes and progression along with proper low-vision services. ●

No identifiable health information was included in this case report

DISCLOSURES

CONTRIBUTORS: All authors contributed to the conception or design of the work, the acquisition, analysis, or interpretation of the data. All authors were involved in drafting and commenting on the paper and have approved the final version.

FUNDING: This case report did not receive any specific grant from funding agencies in the public, commercial, or not-for-profit sectors.

COMPETING INTERESTS: All authors have completed the ICMJE uniform disclosure form and declare no conflict of interest.

ETHICAL APPROVAL: Not required for this article type.

CORRESPONDING AUTHOR: Raman Bhakhri, OD, FAAO – Rbhakhri@ico.edu

REFERENCES

- Huang HB, Zhang YX. Pigmented paravenous retinochoroidal atrophy (Review). *Exp Ther Med*. Jun 2014;7(6):1439-1445. doi:10.3892/etm.2014.1648
- Jung I, Lee Y, Kang S, Won J. Pigmented Paravenous Retinochoroidal Atrophy: A Case Report Supported by Multimodal Imaging Studies. *Medicina (Kaunas)*. 2021. vol. 12.
- Lee EK, Lee SY, Oh BL, Yoon CK, Park UC, Yu HG. Pigmented Paravenous Chorioretinal Atrophy: Clinical Spectrum and Multimodal Imaging Characteristics. *Am J Ophthalmol*. Apr 2021;224:120-132. doi:10.1016/j.ajo.2020.12.010
- Aoki S, Inoue T, Kusakabe M, et al. Unilateral pigmented paravenous retinochoroidal atrophy with retinitis pigmentosa in the contralateral eye: A case report. *Am J Ophthalmol Case Reports*. 2017;12/01/ 2017;8:14-17. doi:10.1016/j.ajoc.2017.08.003
- Shen Y, Xu X, Cao H. Pigmented paravenous retinochoroidal atrophy: a case report. *BMC Ophthalmol*. Jun 7 2018;18(1):136. doi:10.1186/s12886-018-0809-z
- Shona Oa, Islam F, Robson AG, Webster AR, Moore AT, Michaelides M. PIGMENTED PARAVENOUS CHORIORETINAL ATROPHY: Detailed Clinical Study of a Large Cohort. *RETINA*. 2019;39(3)
- McKay GJ, Clarke S, Davis JA, Simpson DA, Silvestri G. Pigmented paravenous chorioretinal atrophy is associated with a mutation within the crumbs homolog 1 (CRB1) gene. *Invest Ophthalmol Vis Sci*. Jan 2005;46(1):322-8. doi:10.1167/iovs.04-0734
- Hughes EH, Guzowski M, Simunovic MP, Hunyor AP, McCluskey P. Syphilitic retinitis and uveitis in HIV-positive adults. *Clin Experiment Ophthalmol*. Dec 2010;38(9):851-6. doi:10.1111/j.1442-9071.2010.02383.x
- Quillen DA, Davis JB, Gottlieb JL, et al. The white dot syndromes. *Am J Ophthalmol*. Mar 2004;137(3):538-50. doi:10.1016/j.ajo.2004.01.053
- Chatziralli I, Saitakis G, Dimitriou E, et al. ANGIOID STREAKS: A Comprehensive Review From Pathophysiology to Treatment. *Retina*. Jan 2019;39(1):1-11. doi:10.1097/iae.0000000000002327
- Triantafylla M, Panos GD, Dardabounis D, Nanos P, Konstantinidis A. Helicoid peripapillary chorioretinal degeneration complicated by choroidal neovascularization. *Eur J Ophthalmol*. Feb 15 2016;26(2):e30-1. doi:10.5301/ejo.5000695
- Barteselli G. Fundus autofluorescence and optical coherence tomography findings in pigmented paravenous retinochoroidal atrophy. *Can J Ophthalmol*. Dec 2014;49(6):e144-6. doi:10.1016/j.jcjo.2014.08.019
- Ranjan R, Jain MA, Verghese S, Manayath GJ, Narendran V. Multimodal imaging of pigmented paravenous retinochoroidal atrophy. *Eur J Ophthalmol*. Jan 2022;32(1):Np125-np129. doi:10.1177/1120672120965489
- Xiang W, Wei Y. Pigmented Paravenous Chorioretinal Atrophy With Macular Hole. *JAMA Ophthalmology*. 2022;140(8):e222437-e222437. doi:10.1001/jamaophthalmol.2022.2437
- Cicinelli MV, Giuffrè C, Rabiolo A, Parodi MB, Bandello F. Optical Coherence Tomography Angiography of Pigmented Paravenous Retinochoroidal Atrophy. *Ophthalmic Surg Lasers Imaging Retina*. May 1 2018;49(5):381-3. doi:10.3928/23258160-20180501-14
- Yanagi Y, Okajima O, Mori M. Indocyanine green angiography in pigmented paravenous retinochoroidal atrophy. *Acta Ophthalmol Scand*. Feb 2003;81(1):60-7. doi:10.1034/j.1600-0420.2003.00003.x
- Foxman SG, Heckenlively JR, Sinclair SH. Rubeola retinopathy and pigmented paravenous retinochoroidal atrophy. *Am J Ophthalmol*. May 15 1985;99(5):605-6. doi:10.1016/s0002-9394(14)77976-0
- Noble KG, Carr RE. Pigmented paravenous chorioretinal atrophy. *Am J Ophthalmol*. Sep 1983;96(3):338-44. doi:10.1016/s0002-9394(14)77825-0
- Xu M, Zhai Y, MacDonald IM. Visual Field Progression in Retinitis Pigmentosa. *Invest Ophthalmol Vis Sci*. Jun 3 2020;61(6):56. doi:10.1167/iovs.61.6.56