

# Curvularia Keratitis: A Fungus Among Us

**Sophia Leung, OD, FAAO,  
FCCSO, Dipl ABO, Dipl AAO**  
Diplomate, Anterior Segment  
Seema Eye Care Center  
Calgary, Alberta, Canada

---

## Abstract

**PURPOSE:** This case demonstrates a less commonly encountered type of fungal keratitis caused by *Curvularia* species and highlights the current standard of care for fungal keratitis.

**CASE REPORT:** A 48-year-old Caucasian woman was referred with a two-week history of a red, painful, and blurry right eye. On biomicroscopic examination, the presence of a white focally elevated infiltrate with feathery borders, an overlying epithelial defect, and satellite lesions led to a clinical diagnosis of fungal keratitis. Culture results suggested that *Curvularia* was the most likely causative organism. This report presents a review of fungal keratitis including treatment strategies based on susceptibility testing and evidence-based reasoning.

**CONCLUSION:** Fungal keratitis is a condition that can initially be misdiagnosed, and delays in treatment can significantly affect visual outcomes. The combination of strong clinical knowledge, communication with local microbiology laboratories, and the ability to adjust treatment strategies during follow-up can help to effectively manage this condition.

**KEY WORDS:** fungal keratitis, *Curvularia*, voriconazole, posaconazole, culture

## INTRODUCTION

Fungal keratitis can account for over 50% of cases of microbial keratitis depending on the geographic location. While visual outcomes vary, fungal keratitis tends to have a worse prognosis than bacterial keratitis.<sup>1</sup> This case report highlights some important considerations when managing fungal keratitis, including recognizing clinical features, the use of culturing, and initiating empirical treatment with the readiness to adjust as necessary.

## CASE REPORT

### Visit 1

A 48-year-old Caucasian woman was referred for a 2-week history of a red, painful, and blurry right eye. She reported that she had used Tobradex (tobramycin 0.3% and dexamethasone 0.1% ophthalmic solution) QID OD for a few days – she had it from a previous infection a few years previously. Her referring primary eye care provider discontinued Tobradex and prescribed Maxitrol (dexamethasone/neomycin/polymyxin B sulfate) ointment QID and Ocuflox (ofloxacin 0.3% ophthalmic solution) QID OD. The patient reported having been at a garden festival a few weeks prior but denied any ocular trauma. Personal ocular history included extended wear of soft contact lenses. Personal medical history included a chronic heart condition, no previous surgeries, no systemic medications, and no known medication allergies. She was alert to time, person, and place.

Aided visual acuities with spectacles were 20/30 OD PH NI and 20/20 OS. Intraocular pressures by applanation were 10 mmHg OD and 12 mmHg OS. Relevant clinical findings in the right eye included a 1.75 mm vertical by 1.65 mm horizontal corneal lesion located mid-peripheral nasally with white fluffy borders, slight stromal elevation, and overlying epithelial defect measuring 1.5 mm vertically and 1.3 mm horizontally that stained with fluorescein (Figure 1). Two satellite lesions with minimal punctate staining,

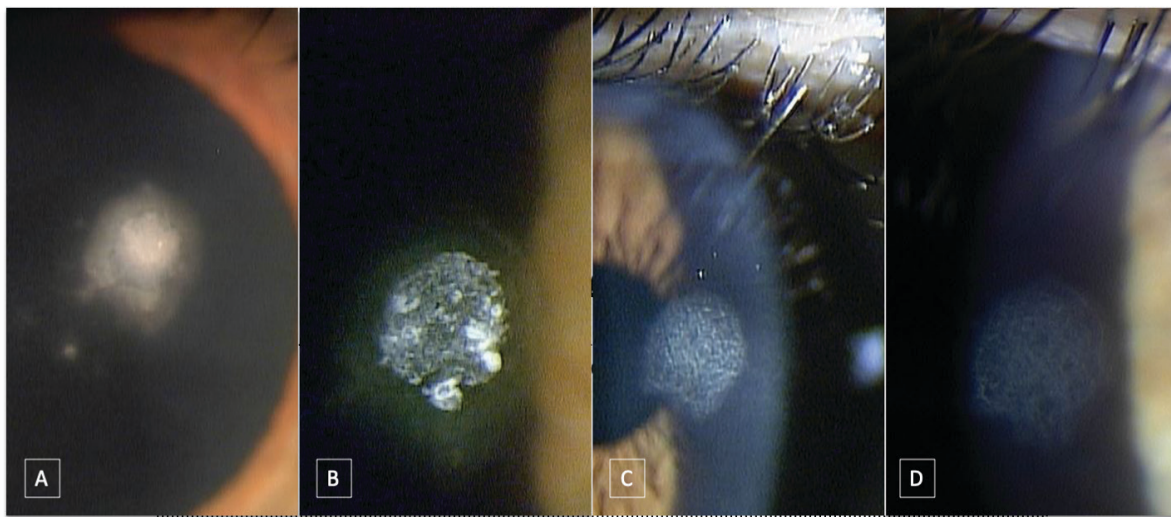
inferior to the larger lesion with similar borders were also noted in the right eye. Grade 1 corneal edema and corneal haze were present OD and the anterior chamber was deep and quiet OD. Anterior segment findings OS and posterior segment findings (assessed with dilation) OD and OS were unremarkable.

Fungal keratitis OD was suspected. The larger ulcer was scraped and cultured on four growth media plates: blood agar, chocolate agar, MacConkey agar, and IMA (inhibitory mold agar) with gentamicin. Maxitrol was discontinued and the patient was prescribed topical natamycin 5% ophthalmic suspension Q1h while awake and Q2h overnight OD. Ocuflox was adjusted to Q2h OD while awake. Contact lens wear was discontinued. A follow-up was scheduled for the next day.

### Visit 2

On Day 2, the patient reported similar vision and symptoms; there had been no worsening. Aided visual acuity with spectacles was 20/30 OD. Anterior segment examination showed a nasal mid-peripherally located 1.75 mm vertical by 1.65 mm horizontal stromal infiltrate and 1.6 mm vertical by 1.5 mm horizontal overlying epithelial defect which stained upon fluorescein instillation (larger than initially noted due to corneal scraping), with white precipitate in the epithelial defect from the topical natamycin OD (Figure 1). Satellite lesions with minimal punctate fluorescein staining were still present in OD. No culture results had been received from the microbiology lab at that time.

**Figure 1:** A. Fungal ulcer with satellite lesions on Day 1. B. Precipitate in fungal ulcer from topical natamycin on Day 2. C. Fading stromal infiltrate with no overlying epithelial defect on Day 15. D. Anterior stromal scar at final follow up on Day 70.



The treatment plan was continued and a follow-up was booked 2 days later.

### Visit 3

On Day 4, the patient reported slight worsening of her symptoms, including foreign body sensation and irritation OD. She reported good compliance with her topical medications. Aided visual acuity was OD 20/40-3 PH NI. Anterior segment examination showed a 1.8 mm vertical by 1.25 mm horizontal stromal infiltrate with a 0.75 mm vertical by 1.0 mm horizontal overlying epithelial defect. The infiltrate appeared to have faded compared to the initial visit, and the epithelial defect was smaller. Satellite lesions were present but also had a fading appearance. No culture results were available at that time.

To decrease the corneal toxicity from the topical medications, topical natamycin was decreased to Q2h while awake and to Q4h overnight OD. Ocuflox was decreased to TID OD. A follow-up was scheduled for the next day.

### Visits 4 and 5

The next two visits were to ensure that the presumed fungal keratitis was not worsening and that the patient's symptoms were improving. The patient reported a slow decrease in discomfort but minimal change in vision. Anterior findings were unchanged. No bacterial growth was reported and was considered to be conclusive at this point by the lab.

No fungal growth was reported. However, since fungal growth can take longer, this was considered a preliminary report. Topical natamycin was decreased to Q3h OD only during waking hours. A follow-up was scheduled for 3 days later.

### Visit 6

On Day 11, the patient reported feeling much better and that her vision had significantly improved. Aided visual acuity was 20/25 OD. Anterior segment examination showed a 1.8 mm vertical and 1.2 mm horizontal fading stromal infiltrate with no epithelial defect. Small satellite lesions with a fading appearance without epithelial staining remained. Preliminary lab results came back positive for fungal growth – *Curvularia* or *Bipolaris* reported. Further speciation and susceptibility testing was requested.

Because of concern for persistent stromal infection, topical natamycin was increased to Q2h while awake plus Q3h overnight OD. Ocuflox TID OD was continued. Oral antifungal medications were discussed as an option to provide broader coverage. The patient noted that she wanted to minimize the possibility of systemic adverse effects in the choice of medications, and oral posaconazole 200 mg BID po was prescribed. A follow-up was scheduled for 4 days later.

### Visit 7

On Day 15, the patient reported that she had run out of topical natamycin. Vision was stable but slight itchiness was reported OD. Aided visual acuity was 20/25-1 OD. Anterior segment showed a 1.75 mm vertical by 1.2 mm horizontal fading stromal infiltrate without any overlying epithelial staining (Figure 1). The satellite lesions which had faded into scars remained similar in size. Minimum inhibitory concentration (MIC) values from the microbiology lab showed that the species grown were most susceptible to amphotericin B and voriconazole. It was suspected to be most likely *Curvularia* but further speciation was not possible per the lab.

Topical amphotericin B 0.15% prepared by a compounding pharmacy was prescribed Q2h while awake and Q3h overnight OD. Oral posaconazole 200 mg BID po and topical Ocuflox TID OD were continued. Topical natamycin was discontinued. A follow-up was scheduled for 2 days later.

### Visit 8

On Day 17, the patient reported similar symptoms and good compliance with treatment. Aided visual acuity was 20/30 OD. Corneal appearance was unchanged OD. Topical amphotericin B was decreased to Q3h including overnight, and all other treatments were continued without changes. A follow-up was scheduled for 4 days later.

### Visit 9

On Day 21, the patient reported that her right eye felt significantly better, and that she felt she could resume normal activities. Aided visual acuity was 20/25 OD. Anterior segment findings included a fading 1.75 mm vertical by 1.2 mm horizontal stromal scar and smaller satellite scars, with no epithelial defects or staining OD. IOP was 16 mmHg OD and 17 mmHg OS.

Topical amphotericin B was decreased to Q4h, including overnight, Ocuflox was decreased to BID, and Lotemax SM (loteprednol etabonate 0.38% ophthalmic gel) BID OD was initiated to decrease stromal inflammation. Oral posaconazole was continued. A follow-up was scheduled for 1 week later.

### Visit 10

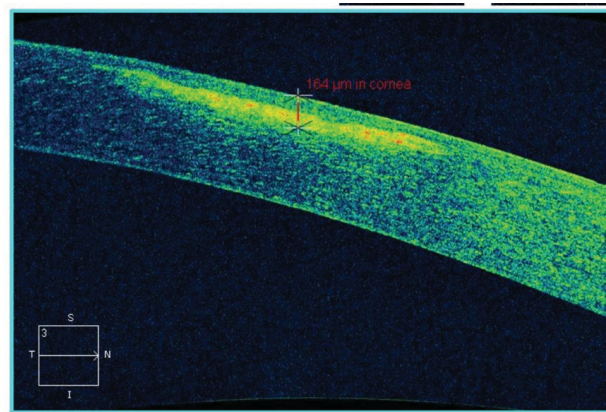
On Day 28, the patient reported no changes; she felt that her right eye was doing well. Aided visual acuity was 20/20-1 OD and 20/20-2 OS. Corneal appearance was stable OD.

Tapering of all medications was initiated – topical amphotericin B was decreased to QID for 1 week, then to TID for another week, BID for another week, and QD for another week before being discontinued OD. Ocuflox was discontinued. Lotemax SM BID OD was continued. Oral posaconazole 200 mg QD was recommended for another 2 months. A follow-up was scheduled for 2 weeks later.

### Visit 11

On Day 42, the patient reported no change in vision or comfort, and good compliance with treatment. Aided visual acuity was unchanged OD and OS. The cornea appeared stable, with evidence of damage from the fungal infection shown as an anterior stromal and sub-epithelial scar (Figure 2). All other findings including posterior segment were unremarkable. Tapering of medications was continued with the exception of Lotemax SM which was continued at BID to be discontinued after 1 month. A follow up was scheduled for 1 month later.

**Figure 2:** Anterior segment OCT 5 Line Raster through stromal scar OD on Day 42. Hyperreflectivity at the anterior stromal layers correspond with irregular collagen from mycotic-related damage.



### Visit 12

On Day 70, the patient returned for her final follow-up. She reported no change in vision or comfort over the last month and good compliance with her medications; she had completed all medication tapering. Aided visual acuity was 20/25+1 OD and 20/20-1 OS. Corneal appearance was stable (Figure 1).

Proper contact lens hygiene was reviewed including caution against overnight wear and a recommendation for switching to daily disposable contact lenses. The patient was released back to her primary eye care provider for a spectacle lenses update and continued routine eye care.

### DISCUSSION

Although typically considered relatively rare, fungal keratitis can account for up to 50% of microbial keratitis cases depending on geographic location.<sup>1,2</sup> It is more common in tropical climates while its incidence is relatively lower in the United States and likely Canada.<sup>1</sup> Fungal keratitis is typically associated with long-term corticosteroid use, chronic contact lens wear, or trauma with exposure to vegetative matter.<sup>1</sup> In certain studies, it is more common in agricultural areas and younger men.<sup>3</sup> Although less common than bacterial keratitis in the US and likely Canada, studies have shown that the visual outcome is worse with fungal keratitis, making this an important condition to diagnose and treat appropriately.<sup>1,4,5</sup>

Important differential diagnoses include bacterial keratitis, other microbial keratitis, or sterile infiltrates. Specific aspects of the lesion's clinical appearance can inform differential diagnosis, and the remainder of this discussion will highlight important practice pearls that clinicians can use to navigate through the diagnosis and management of this condition.

### CLASSIFICATION

The three morphological classifications of fungi in clinical practice are filamentous, yeast, and dimorphic forms.<sup>4</sup>

#### Filamentous

Most commonly found in plants and soil, filamentous fungi are multicellular organisms that have branched hyphae.<sup>4</sup> In tissue, filamentous fungal mycelia extend along the corneal lamellae and potentially can penetrate Descemet's membrane, resulting in intracameral infection.<sup>4</sup> It is the most common cause of mycotic keratitis, particularly in tropical climates, and has been reported to cause over 90% of fungal keratitis cases.<sup>6</sup> *Fusarium* and *Aspergillus* are the most common filamentous fungi to cause mycotic keratitis (over 50% of cases), with pigmented dematiaceous species including *Bipolaris* and *Curvularia* causing between 16 and 19% of infections.<sup>7,8</sup>

Trauma is the most common factor associated with filamentous fungal keratitis, and is found in 40-60% of cases.<sup>3</sup> In *Curvularia* keratitis specifically, trauma has been reported in 72% of cases.<sup>8</sup> *Curvularia* species have been identified as the most prevalent airborne fungal spores, especially in hot and dry climates.<sup>8</sup> *Curvularia* can also grow on soft contact lens materials. For culture purposes, *Curvularia* species have been shown to grow in 2-4 days, on average, with semisynthetic growth media.<sup>8</sup> The pathophysiology of *Curvularia* keratitis is unclear.<sup>8</sup> However, with airborne fungal particles, it is suspected that the specific antigens involved in fungal-associated allergic sinusitis may induce corneal inflammation, thereby breaking down the epithelium as an inflammatory process initially, and forming a

mycotic ulcer as a result of continued exposure to fungal particles.<sup>8</sup>

### Yeast

Yeast forms of fungi are unicellular. They can form either pseudo-hyphae (elongated budding) or true hyphae in tissue. The most common type of yeast in mycotic keratitis is *Candida* species.<sup>4</sup> Though less common in general than filamentous forms, *Candida* is more often causative in temperate climates than in hotter climates.<sup>9</sup> Keratitis caused by yeast is frequently associated with pre-existing ocular surface disease, epithelial compromise with contact lens contamination, and systemic conditions such as diabetes and immunocompromise.<sup>3,4</sup> In fungal endophthalmitis, *Candida* species are the most common cause.<sup>10</sup>

### Dimorphic

Dimorphic forms of fungi reproduce in their yeast phase in tissues but grow in their mycelial phase in culture media. This form has not been documented to cause keratitis but is more commonly associated with posterior segment inflammation. An example of a dimorphic fungus is *Histoplasma* species.<sup>4</sup>

### DIAGNOSIS

Fungal keratitis is typically slow to progress but can have rapid infiltrative development depending on the causative organism and the presence of pre-existing corneal damage.<sup>4,11</sup> A tentative diagnosis is typically made clinically, combining the clinical presentation with consideration of the aforementioned risk factors. The classic appearance of fungal ulcers includes feathery or serrated borders, elevated epithelial slough or infiltration, and non-yellow colouration.<sup>3,4</sup> In the clinical diagnosis, the presence of one of these three features yields a 63% specificity, whereas all three features combined yield a 83% specificity.<sup>3</sup> Satellite lesions are also highly suggestive of fungal keratitis.<sup>1</sup> Conjunctival injection, anterior chamber reaction, and corneal edema may be minimal in early stages, but hypopyon and focal suppuration can be present in advanced stages. Fungal keratitis is most often misdiagnosed as bacterial keratitis or keratitis secondary to *Acanthamoeba* or herpes simplex.<sup>11</sup>

A definitive diagnosis of fungal keratitis requires confirmation by laboratory testing, with the gold standard involving corneal smears or culturing. With corneal smears, Gomori's methenamine silver stain identifies fungal organisms best.<sup>4</sup> Culture media for fungal organisms include Sabouraud's agar, potato dextrose, brain-heart infusion broth, and blood agar.<sup>4</sup> Some studies have found that IMA with gentamicin may be better than Sabouraud's agar for isolating fungal growth in poly-microbial keratitis.<sup>8,12</sup> Typically, fungal organism growth can be demonstrated within a few days, but because some fungal organisms grow relatively slowly in culture, it is imperative to wait two weeks before confirming a negative culture or the absence of fungal growth.<sup>4,8</sup> While *Curvularia* has been shown to grow in various culture media within a few days, it is interesting that the results for the patient in this case report did not come back until Day 11; the microbiology lab was unable to explain why this was the case.

The culture positivity rate is approximately 50% for microbial keratitis in general, and approximately 75% for fungal keratitis.<sup>1,13</sup> Positivity rates for corneal smears have been inconsistently reported in studies<sup>1,4</sup>, and therefore, in our practice, cultures are performed more commonly than smears. Anecdotally, the greatest microbial yield is at the base of the ulcer and the leading edges of the infiltrate, being mindful of any corneal thinning to avoid iatrogenic perforation.<sup>14</sup> Not every local microbiology laboratory performs susceptibility testing. If available, it is imperative to request follow-up susceptibility testing despite having ordered it initially; many labs will not perform susceptibility testing again unless requested, likely because this step has to be outsourced. The microbiology lab was unable to explain why the redundancy in requesting susceptibility testing was required. Even though the susceptibility results were not obtained until Day 15, they were still significant for developing the treatment plan for this patient during follow-up, as it led to a change in medications which allowed for a better treatment response.

Other laboratory tests include polymerase chain reaction techniques, *in vivo* confocal microscopy, and corneal biopsy if corneal tissue has re-epithelialized over the fungal lesions and deeper stromal layers are involved.<sup>4</sup> In this case, the stromal involvement was very shallow and the overlying epithelial layers were not intact at presentation.

### Curvularia keratitis

*Curvularia* keratitis tends to be much slower to progress than the more commonly investigated *Fusarium* keratitis, and tends to present with much less inflammation than other fungal keratitis.<sup>6,7</sup> Wilhelmus and Jones observed that typical diagnoses of *Curvularia* keratitis can take over a week from the time of infection due to patients' delays in seeking care.<sup>8</sup> Its symptoms develop relatively slowly and more insidiously, although peripheral corneal locations of *Curvularia* ulcers present with increased suppuration which can mimic bacterial keratitis.<sup>8</sup> In chronic and advanced cases, there may also be pigment present within the fungal ulcers due to melanin in *Curvularia* cellular walls



(recall its classification as a pigmented dematiaceous fungus).<sup>8</sup> Although certain clinical features can inform the diagnosis, laboratory confirmation is extremely helpful to direct treatment.

In this patient, no history of trauma was present. However, her recent visit on a garden tour, history of extended-wear contact lenses, clinical appearance, and culture results contributed to the definitive diagnosis of fungal keratitis, most likely *Curvularia* keratitis.

### TREATMENT

There are two main classes of anti-fungal medications, polyenes and azoles; other less commonly-used medications include pyrimidine flucytosine and echinocandins.<sup>2</sup> The management of fungal keratitis most commonly involves topical treatment because the role of oral antifungal medications has not been clearly defined.<sup>2</sup>

#### Polyenes

Polyenes attack fungal cell walls and are especially effective against filamentous and yeast forms.<sup>2</sup> However, at therapeutic doses, there is toxicity to human tissue.<sup>2,4</sup> Examples of this class include natamycin and amphotericin B.<sup>2</sup>

Topical natamycin 5% has broad-spectrum coverage that is dose dependent, and is the only FDA-approved topical medication for mycotic keratitis.<sup>2</sup> It is the preferred drug for filamentous fungal keratitis.<sup>4</sup> The recommended dosage is initially Q1-2h in the affected eye, tapered according to the therapeutic response.<sup>2,4</sup> It has no effect on bacteria so coverage with topical antibiotics in the case of polymicrobial keratitis should be considered.<sup>4</sup> Known adverse effects include mild irritation, redness, foreign body sensation, and precipitation or particle suspension in the epithelium, which was demonstrated in this case.<sup>2</sup> There have been very few studies on the application of oral natamycin for fungal keratitis.

Topical amphotericin B 0.15% is highly effective against yeast but less so against filamentous species.<sup>4</sup> It is the drug of choice in *Candida*-associated keratitis.<sup>4</sup> Oral amphotericin B does not reach ocular therapeutic levels and has systemic side effects including renal failure and hepatotoxicity, limiting its routine use in fungal keratitis.<sup>2,4</sup> However, because side effects with oral amphotericin B are dose-dependent and can be managed, it is a category B medication and the safest FDA-approved oral antifungal medication for pregnancies.<sup>2,4</sup> Interestingly, susceptibility testing in this case found that the *Curvularia* species isolated was most susceptible to amphotericin B and voriconazole rather than natamycin.

One main limitation to topical polyenes is poor penetration through an intact cornea.<sup>2</sup> In such cases, epithelial debridement, oral antifungal medication, or subconjunctival or intracameral injection of medication may be required, depending on the severity of the infection. However, studies on these additional steps have been inconclusive.

#### Azoles

Azoles inhibit fungal cell-wall synthesis.<sup>2</sup> Examples of this class include ketoconazole, fluconazole, voriconazole, and posaconazole.<sup>2,4</sup>

Voriconazole is a broad-spectrum anti-fungal medication: its efficacy is dose dependent, but it is fungicidal at low concentrations.<sup>2,4</sup> It is particularly effective against *Aspergillus*, yeast, and dimorphic fungi. It has good corneal penetrance and is a good alternative if topical natamycin results in a limited response.<sup>2,4</sup> Oral voriconazole is FDA-approved for invasive and refractory filamentous infections.<sup>2</sup> Adverse effects include visual changes (somewhat hallucinogenic), cardiac changes such as QT prolongation, bone toxicity, and hepatotoxicity.<sup>2</sup> It is a category D medication and liver function must be monitored during its use.<sup>2</sup> In the Mycotic Ulcer Treatment Trial Part II, the addition of oral voriconazole to topical natamycin in *Fusarium* keratitis was not associated with a statistically significant improvement when compared to topical natamycin alone; however, a subgroup analysis showed less corneal perforation when oral voriconazole was included in the treatment plan.<sup>2</sup> Therefore, standard of care for *Fusarium* keratitis is topical natamycin and oral voriconazole in certain cases, such as slow or minimal epithelial healing, persistent stromal inflammation, ocular surface co-morbidities like dry eye disease, rosacea keratopathy, and herpetic keratopathy.<sup>2,4</sup>

On the other hand, topical voriconazole for fungal keratitis is considered off-label use, although it has been accepted as a good alternative in cases that are unresponsive to topical natamycin.<sup>2</sup> However, in the majority of cases, topical natamycin gave better visual outcomes and lower rates of perforation compared to topical voriconazole for *Fusarium* keratitis in the Mycotic Ulcer Treatment Trial Part I.<sup>4</sup>

Posaconazole is a second-generation azole similar to voriconazole. It is broad-spectrum and non-inferior to other medications within its class.<sup>2</sup> Oral posaconazole has been shown to be effective in fungal keratitis, including cases that are non-responsive or resistant to natamycin, voriconazole, and amphotericin B.<sup>2</sup> It has delayed-release prop-

erties and has been studied at 200 mg po QD up to QID.<sup>2</sup> Systemic adverse effects include fever, diarrhea, nausea, and headaches; hepatotoxicity and QT prolongation are also possible, but are less common than with the use of oral voriconazole.<sup>15</sup> It is a category C medication and has been shown to be well tolerated with chronic use.<sup>2,15</sup> However, it tends to be more expensive than oral voriconazole.<sup>2,15</sup> The patient in this case expressed concern with the known adverse side effects of voriconazole and elected to take posaconazole instead. The decision for additional oral anti-fungal medication was made in consideration of the two-week delay from onset of symptoms to diagnosis and the relatively slow stromal improvement. An oral azole was chosen over an oral polyene medication to allow for broader coverage, as culture results had not been received at the time of prescribing.

### Other anti-fungal medications

Echinocandins and flucytosine are examples of other classes of anti-fungal medications that have applications in systemic fungal infections, although their topical use for fungal keratitis is limited at this time.<sup>2</sup> Specifically, flucytosine has little effect on filamentous species.<sup>2</sup>

### TREATMENT RECOMMENDATIONS

It is imperative that empirical treatment is initiated and continued while waiting on culture results. Topical natamycin dosed frequently, with oral voriconazole or posaconazole considered in cases of stromal infection, is becoming more accepted as the standard of care for fungal keratitis. The treatment duration is much longer than for other corneal infections: in general, treatment for fungal keratitis may last 12 weeks, while more specifically, cases of *Curvularia* keratitis are treated for a mean duration of 40 days.<sup>4,8</sup> This patient was treated for 70 days, but was stable by Day 42.

The role of topical steroids in *Curvularia* keratitis is poorly defined, as studies have been inconclusive.<sup>8</sup> While not recommended in the early stages of active infection, prudent clinical judgment can be used to determine if stromal inflammation remains after signs and symptoms suggest that the active infection has resolved. In this case, it is difficult to say whether the ultimate appearance of the residual stromal scar would have differed much with or without the addition of Lotemax SM.

In 15-20% of typically more severe cases, medical management fails, and lamellar keratectomy or therapeutic keratoplasty may be required.<sup>4,8</sup> The development of newer drug-delivery options such as nanoparticles and improved testing methods such as next-generation sequencing may allow for more effective treatment, as well as faster speciation and susceptibility testing.<sup>1</sup>

### CONCLUSION

Fungal keratitis can be easily misdiagnosed and mistreated if not properly evaluated and followed. Although relatively rare, it can result in significant visual morbidity and visually significant scarring can be permanent. This case of *Curvularia* keratitis demonstrated the benefit of combining clinical knowledge, appropriate laboratory testing, and the ability to adjust treatment plans during follow-up, which resulted in a positive outcome for the patient.

It is vitally important to recognize the behaviour of normal corneal healing at all layers. A mycotic ulcer can re-epithelialize with a remaining stromal response despite still having active infection. Judicious monitoring of the clinical response, timely medication adjustment, corneal culturing, and efficient referral practices can make the difference in saving a patient's sight. Not all fungal keratitis cases end as positively as this one, and it is not impossible to encounter a fungus in everyday practice. ●

### DISCLOSURES

**CONTRIBUTORS:** All authors contributed to the conception or design of the work, the acquisition, analysis, or interpretation of the data. All authors were involved in drafting and commenting on the paper and have approved the final version.

**FUNDING:** This study did not receive any specific grant from funding agencies in the public, commercial, or not-for-profit sectors.

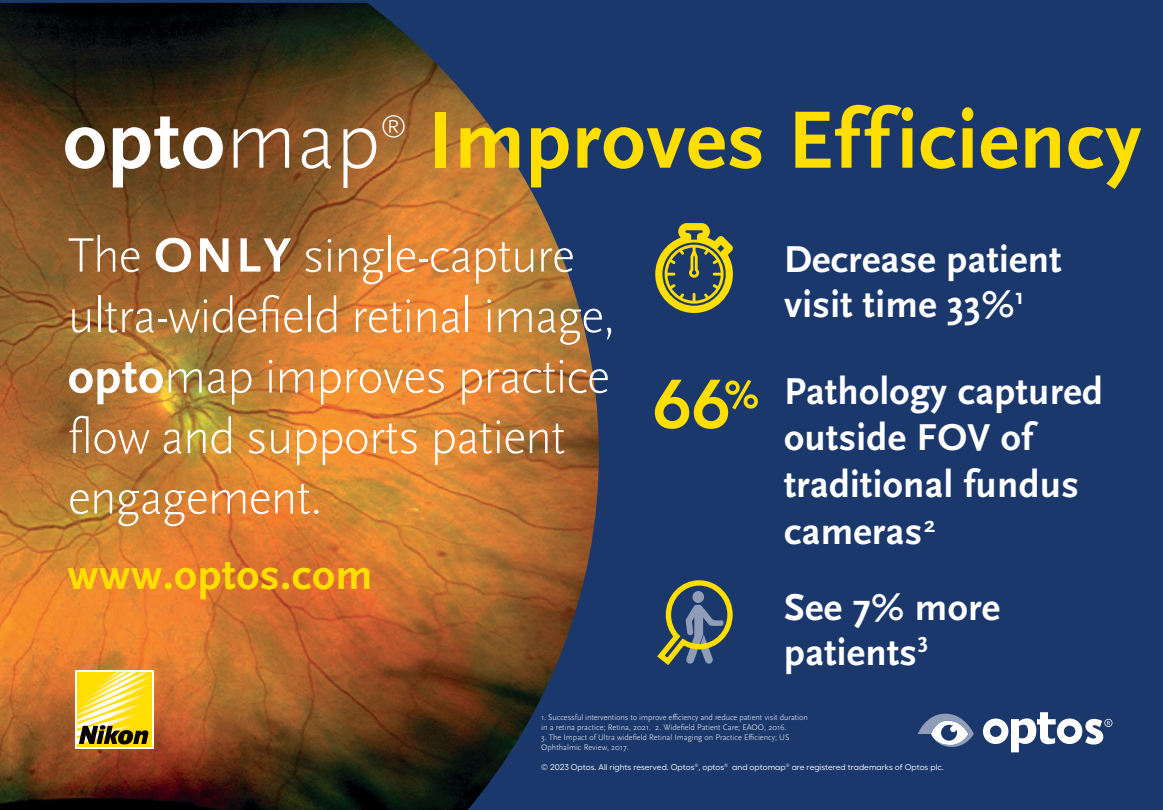
**COMPETING INTERESTS:** All authors have completed the ICMJE uniform disclosure form and declare no conflict of interest.

**ETHICAL APPROVAL:** Not required for this article type.

**CORRESPONDING AUTHOR:** Sophia Leung — sophialeung.od@gmail.com

## REFERENCES

1. Ung L, Bispo PJM, Shanbhag SS, Gilmore MS, Chodosh J. The persistent dilemma of microbial keratitis: Global burden, diagnosis, and antimicrobial resistance. *Surv Ophthalmol*. 2019;64(3):255-271. doi:10.1016/j.survophthal.2018.12.003
2. Sahay P, Singhal D, Nagpal R, et al. Pharmacologic therapy of mycotic keratitis. *Surv Ophthalmol*. 2019;64(3):380-400. doi:10.1016/j.survophthal.2019.02.007
3. Thomas PA, Kalliamurthy J. Mycotic keratitis: Epidemiology, diagnosis and management. *Clin Microbiol Infect*. 2013;19(3):210-220. doi:10.1111/1469-0691.12126
4. Keenan JD, McLeod SD. 4.13 - Fungal Keratitis. Fifth Edit. Elsevier Inc.; 2019. doi:10.1016/B978-0-323-52819-1.00215-2
5. Prajna N V, Srinivasan M, Mascarenhas J, et al. Visual Impairment in Fungal Versus Bacterial Corneal Ulcers 4 Years After Successful Antimicrobial Treatment. *Am J Ophthalmol*. 2019;204:124-129. doi:10.1016/j.ajo.2019.03.010
6. Thomas PA. Fungal infections of the cornea. *Eye*. 2003;17(8):852-862. doi:10.1038/sj.eye.6700557
7. Brandt ME, Warnock DW. Epidemiology, Clinical Manifestations, and Therapy of Infections Caused by Dematiaceous Fungi. 2003.
8. Wilhelmus KR, Jones DB, Gottsch JD. Curvularia keratitis. *Trans Am Ophthalmol Soc*. 2001;99:111-132.
9. Manikandan P, Abdel-Hadi A, Randhir Y, et al. Antifungal Susceptibilities of Fusarium and Aspergillus Isolates from Corneal Scrapings. 2019;2019. doi:10.1155/2019/6395840
10. Durand ML. Bacterial and fungal endophthalmitis. *Clin Microbiol Rev*. 2017;30(3):597-613. doi:10.1128/CMR.00113-16
11. Stagner AM, Jakobiec FA, Eagle RC, Charles NC. Infections of the Eye and Its Adnexa. *Diagnostic Pathol Infect Dis*. 2018:648-685. doi:10.1016/B978-0-323-44585-6.00021-7
12. Scognamiglio T, Zinchuk R, Gumpeni P, Larone DH. Comparison of inhibitory mold agar to sabouraud dextrose agar as a primary medium for isolation of fungi. *J Clin Microbiol*. 2010;48(5):1924-1925. doi:10.1128/JCM.01814-09
13. Mahdy RA, Nada WM, Wageh MM. Topical amphotericin B and subconjunctival injection of fluconazole (Combination Therapy) versus topical amphotericin B (Monotherapy) in treatment of keratomycosis. *J Ocul Pharmacol Ther*. 2010;26(3):281-285. doi:10.1089/jop.2010.0005
14. Robinson J, Ellen J, Hadel B, Lighthizer N. Collecting a corneal culture. Review of Optometry. <https://www.reviewofoptometry.com/article/collecting-a-corneal-culture>. Published 2016. Accessed November 18, 2019.
15. Tang L, Yang XF, Qiao M, et al. Posaconazole vs. voriconazole in the prevention of invasive fungal diseases in patients with haematological malignancies: A retrospective study. *J Mycol Med*. 2018;28(2):379-383. doi:10.1016/j.mycmed.2017.11.003




**optomap<sup>®</sup> Improves Efficiency**


The **ONLY** single-capture ultra-widefield retinal image, **optomap** improves practice flow and supports patient engagement.

[www.optos.com](http://www.optos.com)



 **Decrease patient visit time 33%<sup>1</sup>**

**66%**  **Pathology captured outside FOV of traditional fundus cameras<sup>2</sup>**

 **See 7% more patients<sup>3</sup>**



<sup>1</sup> Successful interventions to improve efficiency and reduce patient visit duration in a retina practice. *Retina*, 2011. <sup>2</sup> Widefield Patient Care. IFAO, 2016. <sup>3</sup> The Impact of Ultra widefield Retinal Imaging on Practice Efficiency. US Ophthalmic Review, 2017.

© 2023 Optos. All rights reserved. Optos<sup>®</sup>, optos<sup>®</sup> and optomap<sup>®</sup> are registered trademarks of Optos plc.